



OFFICE of the WAYNE COUNTY MEDICAL EXAMINER

1300 East Warren Avenue  
Detroit, MI 48207

POST MORTEM REPORT

M.E. CASE NUMBER  
09-10481  
COUNTY OF DEATH  
WAYNE  
TOWN OF DEATH  
DEARBORN  
DATE PRONOUNCED DEAD  
Oct 28, 2009

THIS IS TO CERTIFY THAT John Bechinski, D.O., Assistant Medical Examiner	PERFORMED A POSTMORTEM EXAMINATION ON THE BODY ABDULLAH, LUQMAN AMEEN
AT Wayne County Medical Examiner's Office	ON Oct 29, 2009

SUMMARY & OPINION

It is my opinion that death was caused by multiple gunshot wounds (21).

They were distributed on the chest (2), abdomen (4), left inguinal region (1), left hip and flank (4), left thigh (7), scrotum (1), right inguinal region (1), and back (1).

GUNSHOT WOUND #1:

There was a gunshot wound on the upper right chest. The bullet passed through the chest soft tissue, grazed the right clavicle, and passed into the soft tissue of the right base of the neck. The wound track was from front to back, slightly right to left and upward. A deformed bullet jacket was recovered from the end of the wound track.

GUNSHOT WOUND #2:

There was a gunshot wound on the upper right chest. The bullet passed through the chest soft tissue, front right rib cage, perforated the right lung, passed through the thoracic inlet and into the soft tissue of the right base of the neck. The wound track was from front to back, slightly right to left and upward. A well-preserved jacketed bullet was recovered from the end of the wound track.

GUNSHOT WOUND #3:

There was a gunshot wound on the upper abdomen with adjacent discontinuous abrasions above and below it. The bullet passed through the abdominal soft tissue, liver, perforated the stomach and left kidney, and came to rest in the soft tissue of the back left rib cage. The wound track was from front to back, right to left, and downward. A deformed bullet jacket was recovered from the end of the wound track.

GUNSHOT WOUND #4:

There was a gunshot wound on the left mid-back. The bullet passed through the back soft tissue and back left rib cage, and passed into the left lung. The wound track was from back to front, slightly left to right and sharply upward. A deformed bullet jacket was recovered from the end of the wound track.

GUNSHOT WOUND #5:

There was a gunshot wound on the upper left abdomen. The bullet passed through the abdominal soft tissues, omentum, perforated the transverse colon, pulpified the liver, perforated the right hemidiaphragm and right lung, and passed through the back right rib cage and into the soft tissues of the upper right back. The wound track was from front to back, left to right and upward. A deformed jacketed bullet was recovered from the end of the wound track.

GUNSHOT WOUND #6:

There was a gunshot wound on the umbilicus. The bullet passed through the abdominal soft tissue, omentum, multiple loops of small intestine, mesentery, left hemidiaphragm, and into the left chest cavity. The wound track was from front to back, right to left and upward. A deformed bullet jacket was recovered from the end of the wound track.

GUNSHOT WOUND #7:

There was a gunshot wound on the lower left abdomen. The bullet passed through the abdominal soft tissue, omentum, multiple loops of small intestine, mesentery, pulpified the liver, perforated the right lung, passed through the side and back of the right rib cage and into the soft tissue of the side and back of the right chest. The wound track was from front to back, left to right and upward. A deformed jacketed bullet was recovered from the end of the wound track.

GUNSHOT WOUND #8:



OFFICE of the WAYNE COUNTY MEDICAL EXAMINER

1300 East Warren Avenue  
Detroit, MI 48207

POST MORTEM REPORT

M.E. CASE NUMBER  
09-10481  
COUNTY OF DEATH  
WAYNE  
TOWN OF DEATH  
DEARBORN  
DATE PRONOUNCED DEAD  
Oct 28, 2009

There was a gunshot wound on the left groin. The bullet passed through the groin, omentum and mesentery, perforated multiple loops of small intestine, tore the right kidney, pulpified the right adrenal gland, and ended in the liver. The wound track was from front to back, left to right and upward. A deformed bullet jacket was recovered from the end of the wound track and a bullet fragment was recovered from the mesentery.

GUNSHOT WOUNDS #9, #10, AND #11:

There was a cluster of 3 gunshot wounds on the left flank and left hip. The bullets passed through the left pelvic bone, fractured it, perforated multiple loops of small intestine and descending colon, mesentery and pancreas, pulpified the spleen and the left kidney, perforated the abdominal aorta, pulpified the liver, passed through the diaphragm, perforated the pericardium, heart, and the right lung, side and back of the right rib cage and ended in the soft tissue of the right chest. The wound tracks were from slightly front to back, left to right and upward. Two deformed jacketed bullets and one deformed bullet jacket and bullet fragment were recovered from the end of the wound tracks.

GUNSHOT WOUND #12:

There was a through and through gunshot wound on the left hip. The bullet passed through the hip soft tissue, fractured the left pelvic bone, traversed the groin soft tissue, and exited on the left groin. The wound track was from back to front, left to right and downward.

GUNSHOT WOUNDS #13, #14, #15, #16, #17 AND #18:

This was a cluster of 6 gunshot wounds on the left thigh. The bullets passed through the thigh and pelvic soft tissue, fractured pelvic bones, perforated the right and left common iliac artery and vein, rectum, bladder, multiple loops of small intestine, and ended in the soft tissue of the left hip, pelvis, low back, and the spine. The wound tracks were from front to back, left to right and upward. A deformed bullet jacket was recovered from the abdomen, spine, pelvis, and left hip soft tissue, a bullet fragment was recovered from the left hip soft tissue, and 2 deformed bullet jackets were recovered from the left lower back soft tissue.

GUNSHOT WOUND #19:

There was a through and through gunshot wound on the left inner mid-thigh. The bullet passed through the thigh soft tissue, the femur (with a resultant palpable fracture), and exited on the lower front left thigh. The wound track was from slightly back to front, right to left and slightly downward.

GUNSHOT WOUND #20:

There was a through and through gunshot wound on the front and left side of the scrotum. The bullet passed through the scrotal soft tissue, perforated the right testicle, and exited on the right side of the scrotum. The wound track was from front to back, left to right and slightly upward.

GUNSHOT WOUND #21:

There was an irregularly contoured gunshot wound on the right groin. The bullet passed through the soft tissues of the pelvis, where it came to rest, and from where a deformed bullet jacket was recovered. The wound track was from front to back, slightly left to right and upward.

It is likely that GSW #21 is a continuation of GSW #20.

There were many tiny, unrecoverable, metallic fragments, especially in the pelvis, which indicates extensive fragmentation of the projectiles.

There was no soot or gunpowder stippling on the skin around any of the entrance wounds.

The wounds are numbered for descriptive purposes only and do not attempt to depict the sequence in which the wounds occurred.

A deformed bullet jacket was recovered from the black and white strip of cloth.

There were an estimated 1500 ml of blood in the chest as a result of injury to intrathoracic organs.



OFFICE of the WAYNE COUNTY MEDICAL EXAMINER

1300 East Warren Avenue  
Detroit, MI 48207

POST MORTEM REPORT

M.E. CASE NUMBER  
09-10481  
COUNTY OF DEATH  
WAYNE  
TOWN OF DEATH  
DEARBORN  
DATE PRONOUNCED DEAD  
Oct 28, 2009

Additional injuries consisted of an abrasion on the middle of the forehead, right forehead, inner left brow, left upper eyelid, left upper cheek under the eye, left cheek beside the eye, and on the lower right lip. There was a cluster of 7 lacerations on the left lower jaw. Two lacerations were present on the left angle of the mouth. There was a laceration on the lateral upper right lip and buccal mucosa of the lateral lower right lip. There was a fracture of the front of the maxilla.

There was a superficial avulsion on the right index finger and a laceration on the base of the right middle finger. Four lacerations were on the palm of the left hand. Six abrasions were on the left elbow and back left arm, six abrasions were on the inner left arm and front forearm, and two abrasions were on the back left forearm

The manner of death is homicide.

printed by: ci

John Bechinski, D.O., Assistant Medical Examiner

Oct 29, 2009

Carl J. Schmidt, M.D., M.P.H.,  
Chief Medical Examiner

(report continues on next page)



OFFICE of the WAYNE COUNTY MEDICAL EXAMINER

1300 East Warren Avenue  
Detroit, MI 48207

POST MORTEM REPORT

M.E. CASE NUMBER  
09-10481  
COUNTY OF DEATH  
WAYNE  
TOWN OF DEATH  
DEARBORN  
DATE PRONOUNCED DEAD  
Oct 28, 2009

Cause of Death:

MULTIPLE GUNSHOT WOUNDS

Other Significant Conditions:

Manner of Death:

Homicide

NARRATIVE SUMMARY

POSTMORTEM EXAMINATION:

Case Number: 10481 - 09  
Name: Luqman Abdullah  
Date of Pronounced Death: October 28, 2009  
Date of Postmortem Examination: October 29, 2009

EXTERNAL EXAMINATION:

The body was that of a well developed black male appearing about the recorded age of 53 years. The body measured 5 feet 7 inches in length and weighed approximately 174 pounds. The body was cool, rigor mortis was fully developed, and livor mortis was present posteriorly, barely visible and partially fixed. Clothing consisted of 2 white/dark green/maroon shoes, 2 white socks, blue jeans with a black belt, a gray t-shirt, black shirt, a blue denim jacket, black cap, and a black and white strip of cloth. The head was normocephalic and the scalp hair was black and shaved. There was a black beard and mustache. The eyes had white sclerae, pale conjunctivae, and brown irides. The dentition was natural and the upper central incisors were absent. No lesions of the oral mucosa were identified. There were no masses discernable in the neck and the larynx was in the midline. The thorax was symmetrical and the abdomen was flat. The external genitalia were those of a normal adult uncircumcised male. The extremities and back showed no significant deformities. Scars were present on the left hip, right inguinal region, proximal posteromedial right thigh, right knee, left elbow, dorsal left forearm, lower right back, and left buttock.

A tooth fragment and part of a fractured dental accessory were received with the body.

EVIDENCE OF INJURY

GUNSHOT WOUNDS:

There were multiple gunshot wounds (21). These were distributed on the chest (2), abdomen (4), left inguinal region (1), left hip and flank (4), left thigh (7), scrotum (1), right inguinal region (1), and back (1). A deformed bullet jacket was recovered from the black and white strip of cloth. There were an estimated 1500 ml of blood in the chest cavity as a result of injury to intrathoracic organs.

GUNSHOT WOUND #1:

There was a gunshot wound on the upper right chest, 12 inches below the top of the head and 2 1/4 inches right of the



OFFICE of the WAYNE COUNTY MEDICAL EXAMINER

1300 East Warren Avenue  
Detroit, MI 48207

POST MORTEM REPORT

M.E. CASE NUMBER  
09-10481  
COUNTY OF DEATH  
WAYNE  
TOWN OF DEATH  
DEARBORN  
DATE PRONOUNCED DEAD  
Oct 28, 2009

midline. The bullet proceeded from this injury through the chest soft tissues, grazed the right mid-clavicle, and passed into the soft tissue of the lateral right base of the neck. The wound track was from front to back, slightly right to left and upward. A deformed bullet jacket was recovered from the end of the wound track.

GUNSHOT WOUND #2:

There was a gunshot wound on the upper right chest, 14 1/2 inches below the top of the head and 2 1/4 inches right of the midline. The bullet proceeded from this injury through the chest soft tissue, anterior right 2nd intercostal space, perforated the upper lobe of the right lung, passed through the thoracic inlet and into the soft tissue of the posterolateral right base of the neck. The wound track was from front to back, slightly right to left and upward. A well-preserved jacketed bullet was recovered from the end of the wound track.

GUNSHOT WOUND #3:

There was a gunshot wound on the epigastrium, 23 1/2 inches below the top of the head and 1/4 inch right of the midline, with adjacent discontinuous abrasions superior and inferior to the entrance wound that were from 1/4 inch to 3/4 inch in greatest dimension. The bullet proceeded from this injury through the epigastric soft tissue, left lobe of the liver, perforated the stomach and left kidney, and passed into the soft tissue of the posterior left 10th intercostal space. The wound track was from front to back, right to left, and downward. A deformed bullet jacket was recovered from the end of the wound track.

GUNSHOT WOUND #4:

There was a gunshot wound on the lateral left mid-back, 25 inches below the top of the head and 3 1/2 inches left of the midline. The bullet proceeded from this injury through the soft tissues of the back, posterior left 10th intercostal space, lower lobe of the left lung, and into the upper lobe of the left lung. The wound track was from back to front, slightly left to right and sharply upward. A deformed bullet jacket was recovered from the end of the wound track.

GUNSHOT WOUND #5:

There was a gunshot wound on the lateral upper left abdomen, 28 inches below the top of the head and 5 inches left of the midline. The bullet proceeded from this injury through the abdominal soft tissue, omentum, perforated the transverse colon, pulpified the right lobe of the liver, perforated right hemidiaphragm and the lower lobe of the right lung, and passed through the posterior right 4th rib with a resultant fracture and into the soft tissue of the upper right back. The wound track was from front to back, left to right and upward. A deformed jacketed bullet was recovered from the end of the wound track.

GUNSHOT WOUND #6:

There was a gunshot wound on the superior aspect of the umbilicus, 29 inches below the top of the head and on the midline. The bullet proceeded from this injury through the abdominal soft tissue, omentum, multiple loops of small intestine, mesentery, left hemidiaphragm, and into the left pleural cavity. The wound track was from front to back, right to left and upward. A deformed bullet jacket was recovered from the end of the wound track.

GUNSHOT WOUND #7:

There was a gunshot wound on the left lower abdomen, 30 1/2 inches below the top of the head and 1 1/4 inches left of the midline. The bullet proceeded from this injury through the abdominal soft tissue, omentum, multiple loops of small intestine, mesentery, pulpified the right lobe of the liver, perforated the lower lobe of the right lung, passed through the right posterolateral 7th intercostal space and into the soft tissue of the posterolateral right chest. The wound track was from front to back, left to right and upward. A deformed jacketed bullet was recovered from the end of the wound track.

GUNSHOT WOUND #8:



# OFFICE of the WAYNE COUNTY MEDICAL EXAMINER

1300 East Warren Avenue  
Detroit, MI 48207

## POST MORTEM REPORT

M.E. CASE NUMBER  
09-10481  
COUNTY OF DEATH  
WAYNE  
TOWN OF DEATH  
DEARBORN  
DATE PRONOUNCED DEAD  
Oct 28, 2009

There was a gunshot wound on the left inguinal region, 34 inches below the top of the head and 3 inches left of the midline. The bullet proceeded from this injury through the inguinal soft tissue, omentum and mesentery, perforated multiple loops of small intestine, tore the hilum of the right kidney, pulpified the right adrenal gland, and ended in the right lobe of the liver. The wound track was from front to back, left to right and upward. A deformed bullet jacket was recovered from the end of the wound track and a bullet fragment was recovered from within the mesentery.

### GUNSHOT WOUNDS #9, #10, AND #11:

This was a cluster of 3 gunshot wounds on the left flank and left hip, centered 30 inches below the top of the head and on the mid-axillary line. The bullets proceeded from these injuries through the wing of the left ilium (which was fractured), perforated multiple loops of small intestine and descending colon, passed through the mesentery and pancreas, pulpified the spleen and the left kidney, perforated the abdominal aorta, pulpified the right lobe liver, passed through the diaphragm, distal esophagus, pericardium, right and left atria, the lower and middle lobes of the right lung, the lateral-posterior right 6th and 7th intercostal spaces and ended in the soft tissue of the lateral-posterior right chest. The wound tracks were from slightly front to back, left to right and upward. Two deformed jacketed bullets and one deformed bullet jacket and bullet fragment were recovered from the end of the wound tracks.

### GUNSHOT WOUND #12:

There was a through and through gunshot wound on the left hip, 32 1/4 inches below the top of the head and on the mid-axillary line. The bullet proceeded from this injury through the soft tissues of the hip, fractured the wing of the left ilium, traversed the inguinal soft tissue, and exited on the left inguinal region, 34 inches above the left heel and 10 inches below the anterior superior iliac spine. The wound track was from back to front, left to right and downward.

### GUNSHOT WOUNDS #13, #14, #15, #16, #17 AND #18:

This was a cluster of 6 gunshot wounds on the left thigh, centered 31 inches above the heel and 7 inches below the anterior superior iliac spine. The bullets proceeded from these injuries through the thigh and pelvic soft tissue, fractured the bilateral superior pubic rami and wing of the left ilium, perforated the right and left common iliac artery and vein, rectum, bladder, and multiple loops of small intestine, and ended in the soft tissue of the left hip, pelvis, low back, and the body of the 3rd lumbar vertebrae. The wound tracks were from front to back, left to right and upward. Deformed bullet jackets were recovered from the abdomen, body of the 3rd lumbar vertebra, pelvis, and left hip soft tissue, respectively; a bullet fragment was recovered from the left hip soft tissue, and 2 deformed bullet jackets were recovered from the left lower back soft tissue.

### GUNSHOT WOUND #19:

There was a through and through gunshot wound on the medial left mid-thigh, 25 inches above the heel and 13 inches below the anterior superior iliac spine. The bullet proceeded from this injury through the soft tissues of the thigh, fractured the left femur, and exited on the anterior distal left thigh, 24 inches above the heel. The wound track was from slightly back to front, right to left and slightly downward.

### GUNSHOT WOUND #20:

There was a through and through gunshot wound on the anterior and left side of the scrotum, 38 inches below the top of the head. The bullet proceeded from this injury through the scrotum, perforated the right testicle, and exited on the right side of the scrotum, 37 inches below the top of the head. The wound track was from front to back, left to right and slightly upward.

### GUNSHOT WOUND #21:

There was an irregularly contoured gunshot wound on the right inguinal region, 35 inches below the top of the head. The bullet proceeded from this injury through the soft tissue of the pelvis and ended in the right pelvis. The wound track was from front to back, slightly left to right and upward. A deformed bullet jacket was recovered from the end of



OFFICE of the WAYNE COUNTY MEDICAL EXAMINER

1300 East Warren Avenue  
Detroit, MI 48207

POST MORTEM REPORT

M.E. CASE NUMBER  
09-10481  
COUNTY OF DEATH  
WAYNE  
TOWN OF DEATH  
DEARBORN  
DATE PRONOUNCED DEAD  
Oct 28, 2009

the wound track.

It is likely that GSW # 21 is a continuation of GSW # 20.

There were many small metallic fragments in the pelvis.

There was no soot or gunpowder stippling on the skin around any of the entrance wounds.

OTHER INJURIES:

Additional injuries consisted of a 1/2 inch diameter abrasion on the glabella, a 1 inch diameter abrasion on the right forehead, a 1/4 inch diameter abrasion on the medial left brow, a 5/16 inch diameter abrasion on the left upper eyelid, a 3/16 inch diameter abrasion on the left superior maxilla, a 3/4 inch diameter abrasion on the left zygoma, and a 3/16 inch diameter abrasion on the lower right lip.

There was a cluster of 7 lacerations on the left mandibular region that were from 3/16 inch to 1/4 inch long. There were two 1/8 inch long lacerations on the left angle of the mouth. There was a 5/16 inch laceration on the lateral upper right lip. There was a 1/8 inch laceration on the buccal mucosa of the lateral lower right lip. There was a fracture of the central anterior maxilla.

There was a 1/8 inch superficial avulsion on the right 2nd dorsal interphalangeal joint. There was a 1/8 inch laceration on the 3rd dorsal metacarpal phalangeal joint. There were four 1/8 inch lacerations on the palm of the left hand.

There were six abrasions on the left elbow and dorsal left arm that were from 1/8 inch to 3/4 inch in greatest dimension. There were six abrasions on the medial left arm and ventral forearm that were from 1/8 inch to 1/4 inch greatest dimension. There were two abrasions on the dorsal left forearm that were 1/8 inch and 3/16 inch in greatest dimension.

INTERNAL EXAMINATION:

An autopsy was performed utilizing the normal thoraco-abdominal and posterior coronal scalp incisions. Except for the above previously described injuries, the following internal systems were as follows:

**Head:**  
No abnormality was noted in the reflected scalp, calvarium, dura, meninges or the base of the skull. The 1325 gm brain was free of neoplastic and other focal lesions, infarcts, and hemorrhages. The cerebral vascular system was unremarkable.

**Neck:**  
No abnormality was noted in the cervical muscles, hyoid bone, laryngeal cartilages, trachea, or the cervical vertebral column.

**Cardiovascular System:**  
The 325 gm heart had a normal configuration with an unremarkable epicardial surface and a moderate amount of epicardial fat. The coronary arteries had no significant atherosclerotic disease. No acute thrombi were present. Both ventricles were of normal size and their walls were of normal thickness. No focal endomyocardial lesions were present. The papillary muscles and chordae tendineae were not thickened, and the heart valves were unremarkable. The aorta had no significant atherosclerosis. The major arteries and great veins showed normal distribution.

**Respiratory System:**  
The larynx and trachea were unremarkable. The right and left lungs weighed 400 gm and 375 gm, respectively. There was passive congestion in the parenchyma accentuated with dependent lividity. No pulmonary emboli were identified.

**Hepatobiliary System:**



OFFICE of the WAYNE COUNTY MEDICAL EXAMINER

1300 East Warren Avenue  
Detroit, MI 48207

POST MORTEM REPORT

M.E. CASE NUMBER  
09-10481  
COUNTY OF DEATH  
WAYNE  
TOWN OF DEATH  
DEARBORN  
DATE PRONOUNCED DEAD  
Oct 28, 2009

The 1400 gm liver had firm dark tan surfaces and an unremarkable parenchymal pattern. The gallbladder and biliary tracts were unremarkable.

Hemolymphatics:

The 100 gm spleen had smooth surfaces and dark purple firm pulp. There was no significant lymphadenopathy.

Alimentary System:

The tongue, esophagus, stomach, small bowel, appendix and colon were unremarkable. The lining of the stomach had an intact and unremarkable rugal pattern and the contents of the stomach consisted of a scant amount of tan mucoid material.

Pancreas:

The pancreas showed an unremarkable tan lobulated pattern.

Endocrine System:

The thyroid gland had a normal bilobed configuration. The adrenal glands were each unremarkable with golden-yellow cortices.

Genitourinary System:

The right and left kidneys weighed 125 gm and 125 gm, respectively. Each kidney had smooth cortical surfaces, normal cortico-medullary regions, and no changes in the calyceal systems, peives, ureters, or bladder.

Musculoskeletal System:

Except for the above noted injuries, all the muscles and axial skeleton were free of any significant abnormalities.

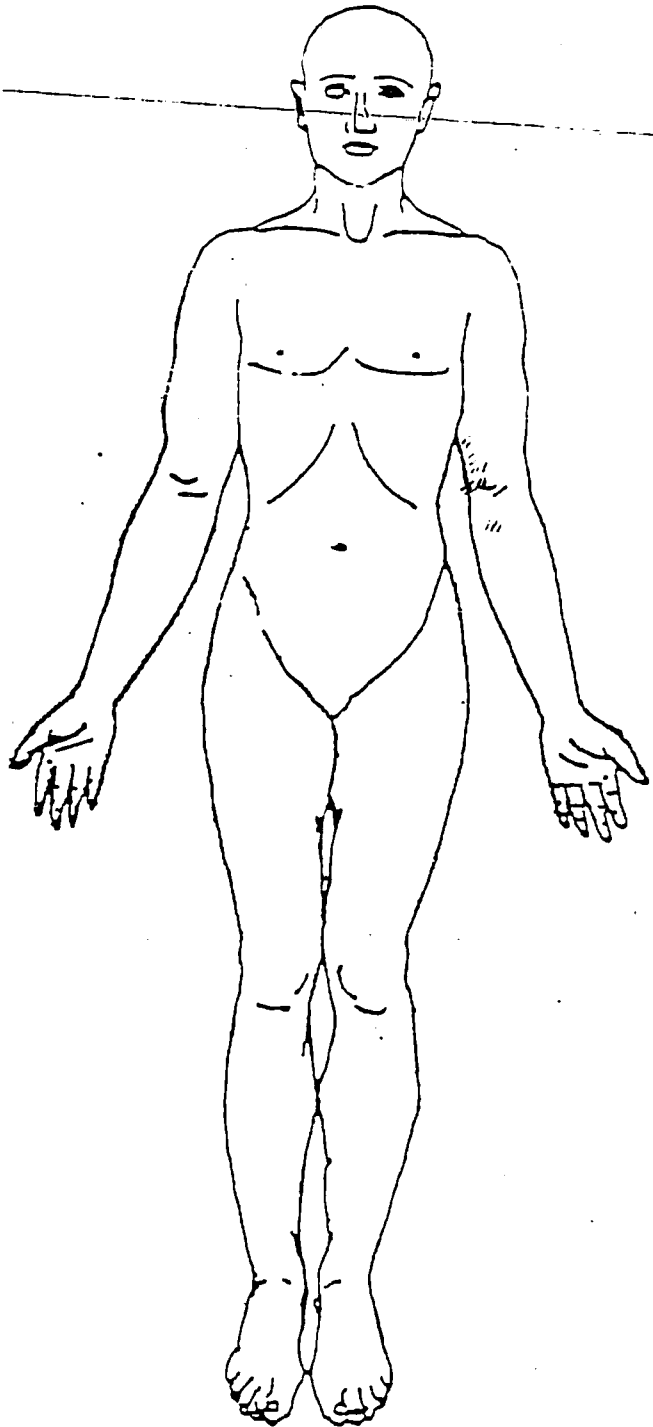
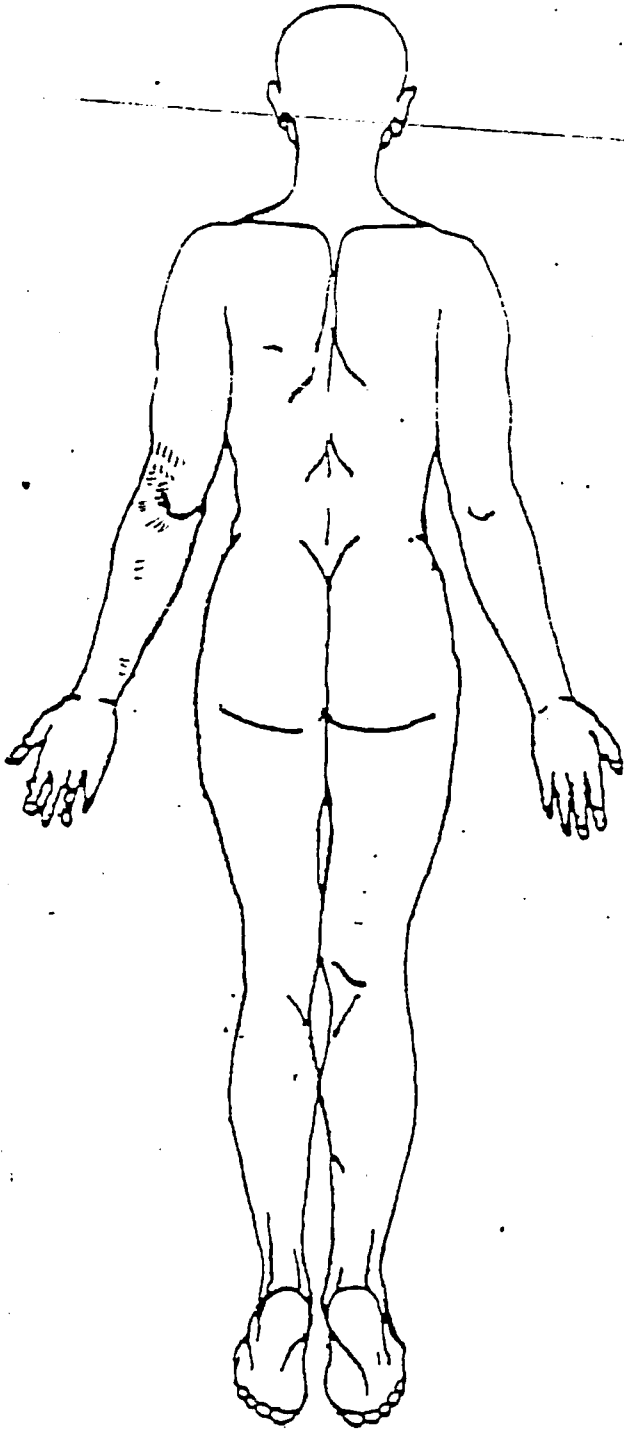
(End of Report)





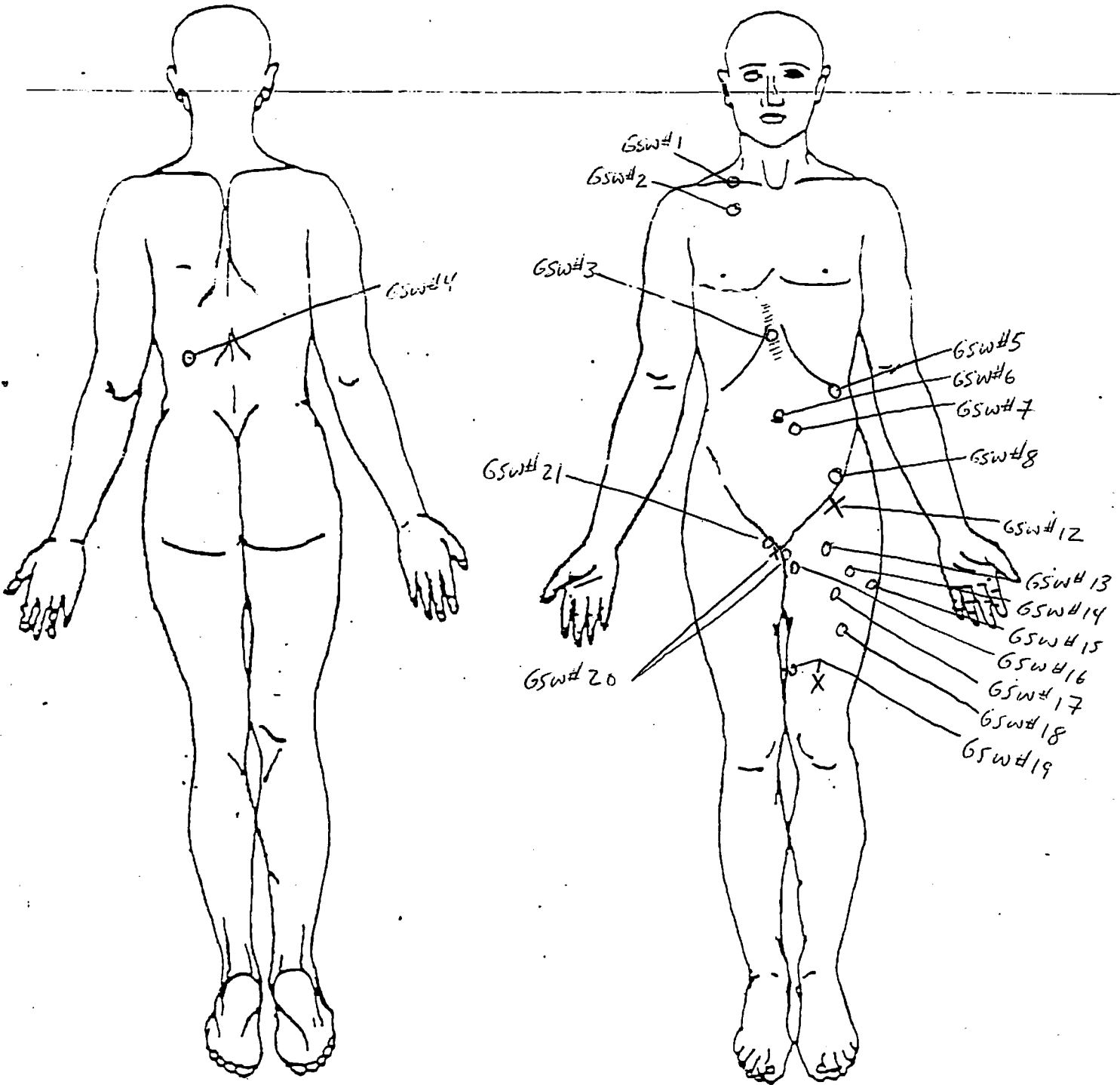
Key  
/// = Abrasion

CASE NO. 09-10481  
Lugman Abdullah



Key  
 GSW: Gunshot Wound  
 O: Entrance Wound  
 X: Exit Wound  
 III: Abrasion

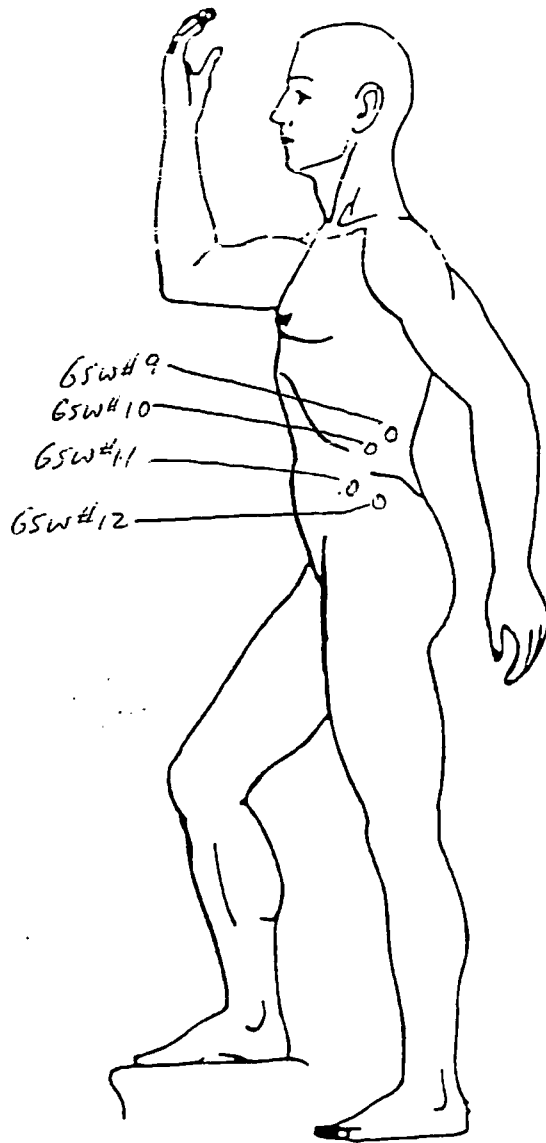
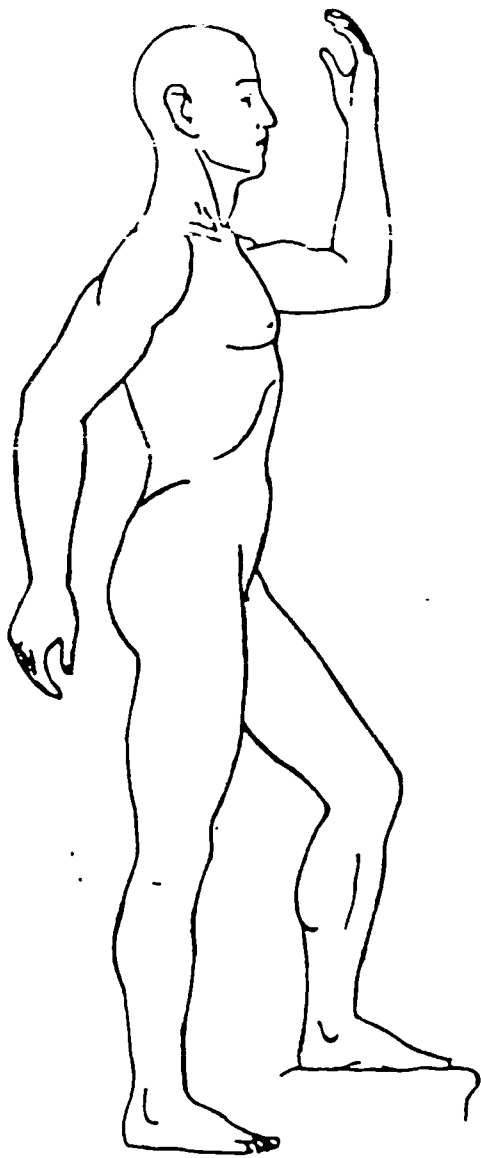
CASE NO. 79-10481  
 Luqman Abdullah



*[Handwritten signature]*

Key  
GSW = Gunshot Wound  
o = Entrance Wound

09-10481  
Luqman Abdullah



Name: Lugman Abdullah

Date \_\_\_\_\_

Sex \_\_\_\_\_ Race \_\_\_\_\_


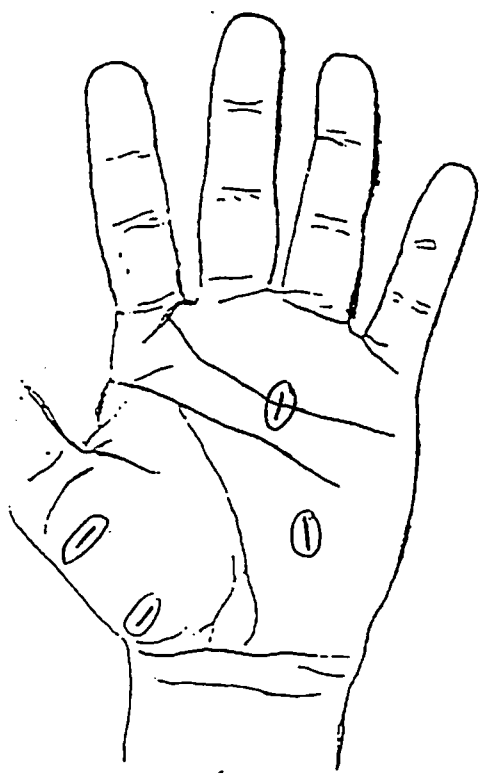

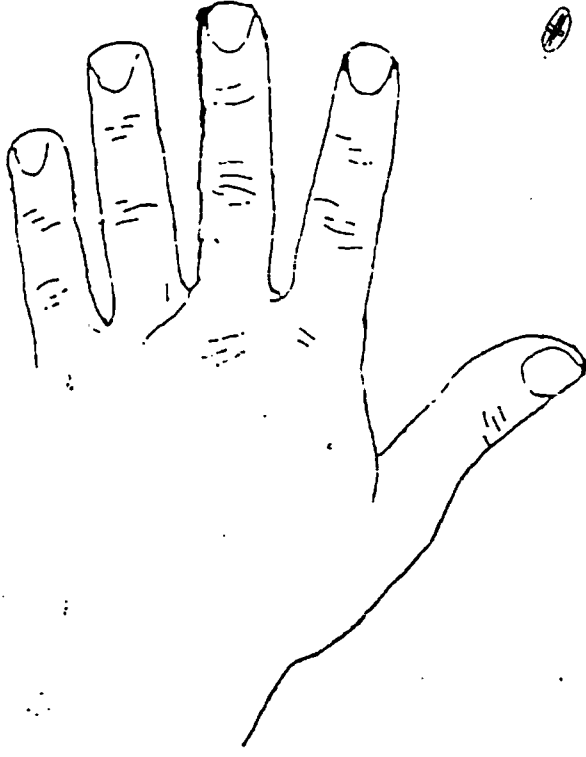
Case No. 09-10481

Autopsy No. \_\_\_\_\_

Key

① = Laceration

⊕ = Superficial Avulsion



Key  
///: Abrasion  
/: Laceration

09-10481  
Lugman Abdullah

